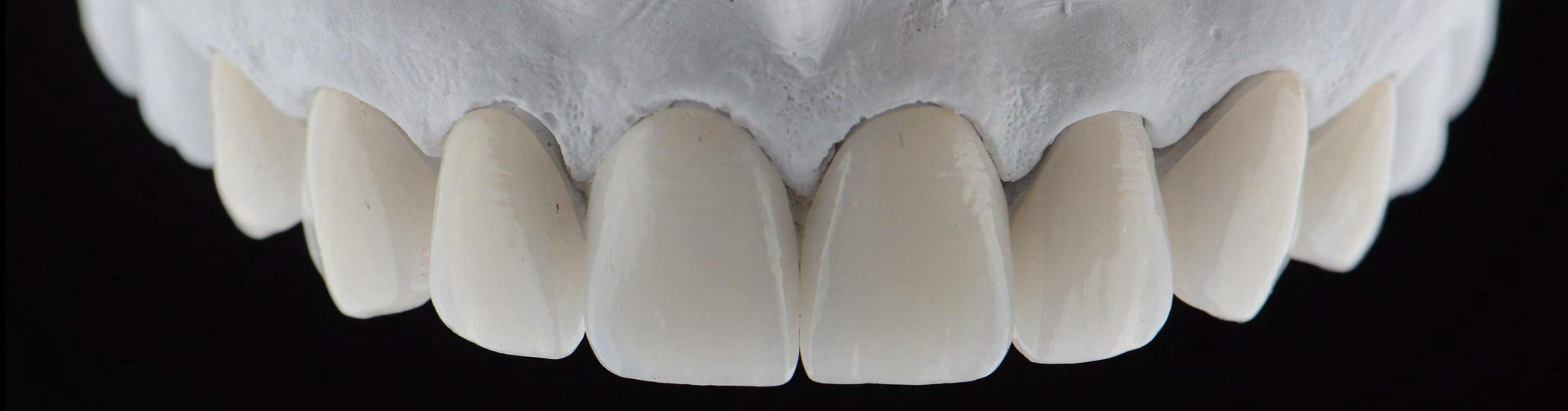



Our mission is to deliver endodontic products and solutions, at a more affordable price which in turn benefits practitioners and patients everywhere.



7 clinical cases made by practitioners

About EdgeEndo




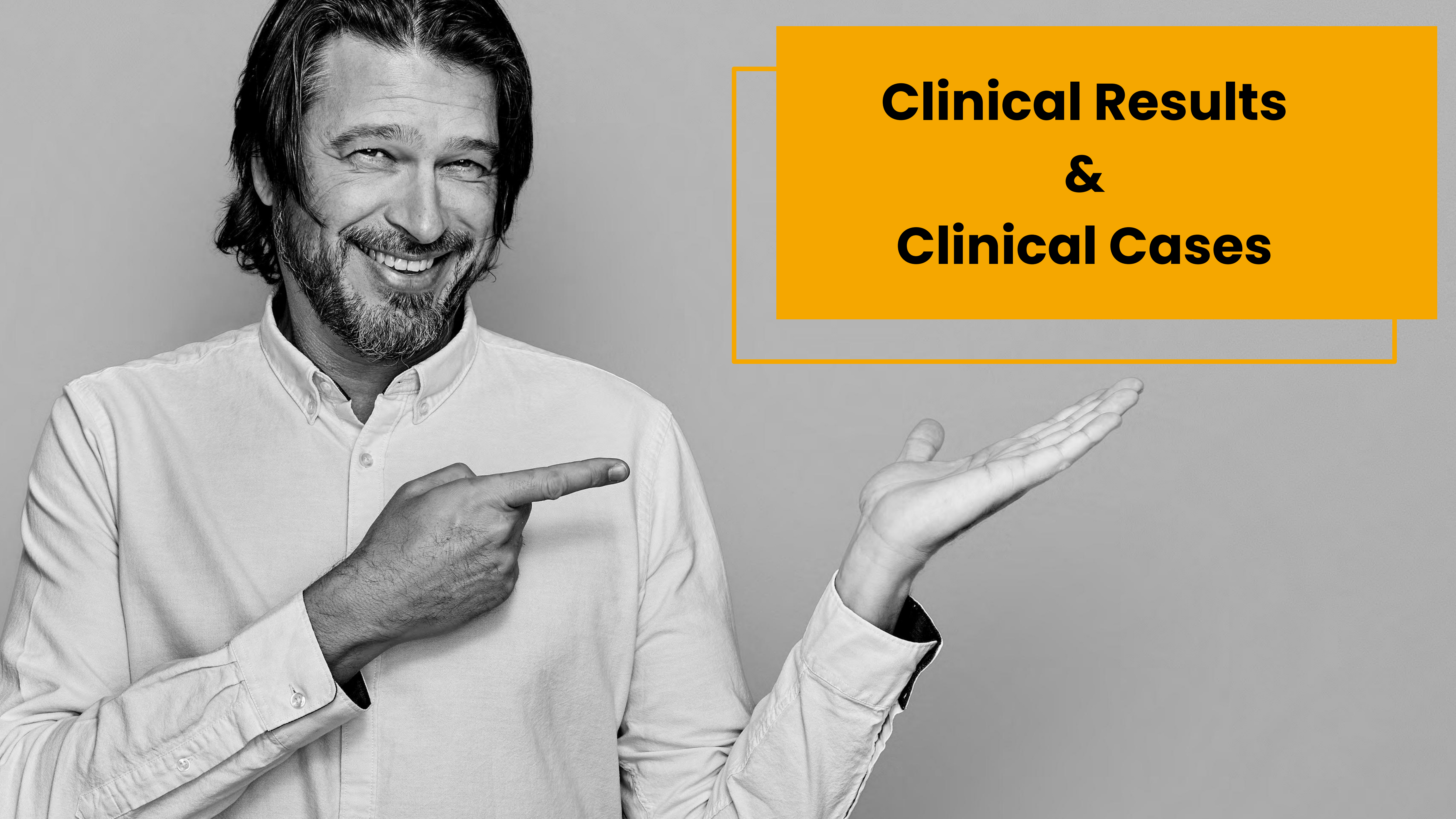
EdgeEndo was founded in 2012 by US based Endodontist, Dr. Charles Goodis. Conducting business in **30+ countries** around the world, EdgeEndo's mission is to deliver high quality dental products and solutions, at affordable prices which in turn benefits practitioners and patients everywhere. Innovation is the heart of EdgeEndo, we believe **premium technology shouldn't have to come with a premium price tag.**



Let Us Help You Do Great Root Canals.

– **Charles J. Goodis,**
DDS, Endodontist,
Albuquerque, NM, USA,
Founder & Owner, EdgeEndo®





**Clinical Results
&
Clinical Cases**



EDGEENDO®

Clinical Case

1



– **James A. Wealleans, D.M.D.**, American Board Certified Endodontist, Adj Professor, Clinician Sydney, Australia

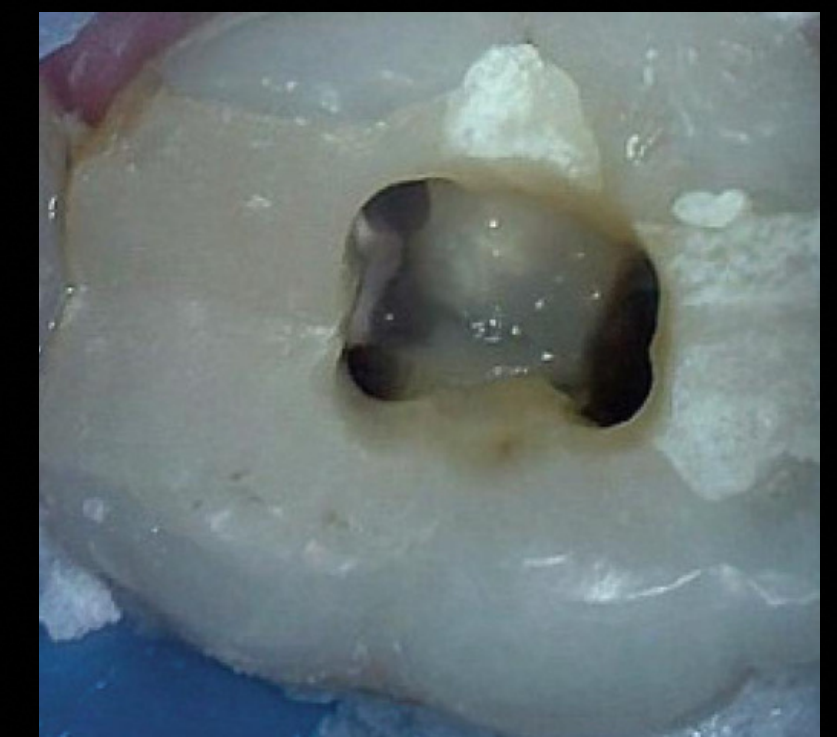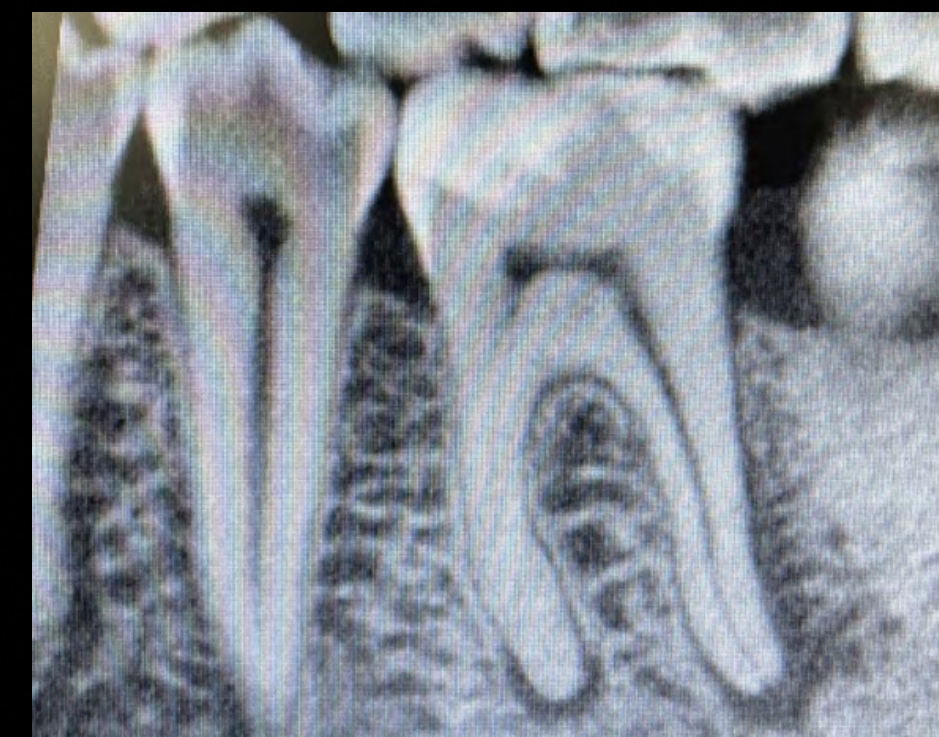
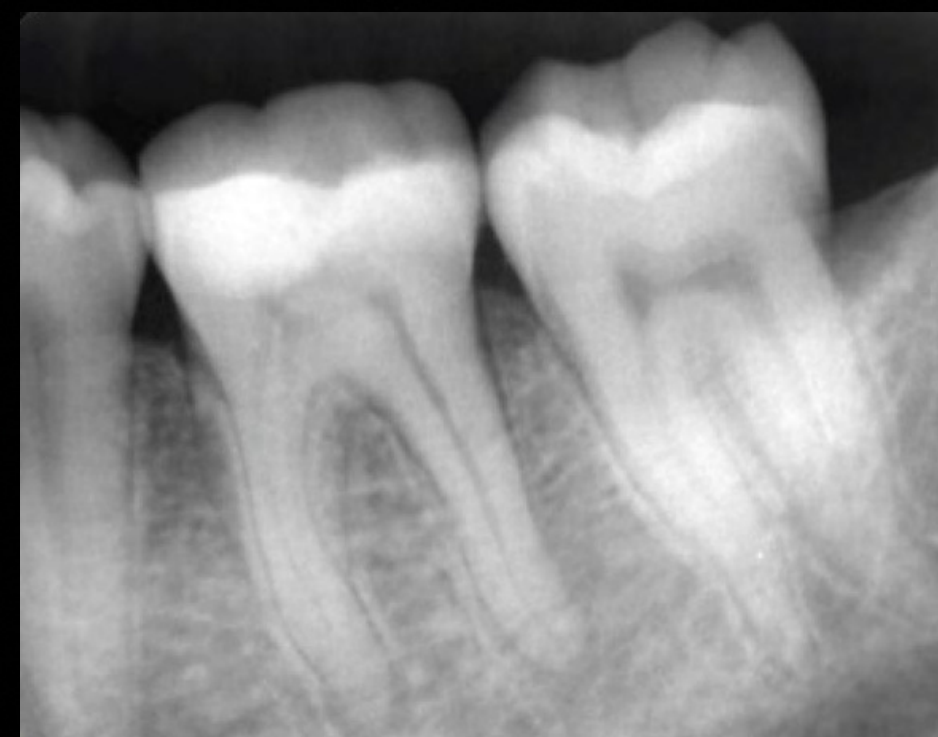The patient was referred to our endodontic practice for evaluation and treatment of tooth 36. Clinically #36 had MOD composite restoration, a negative response to cold, and tenderness to percussion. Pre-op x-ray revealed #36 had a small periapical radiolucency associated with the Mesial root and a moderate size associated with the Distal root.

Pre-Op

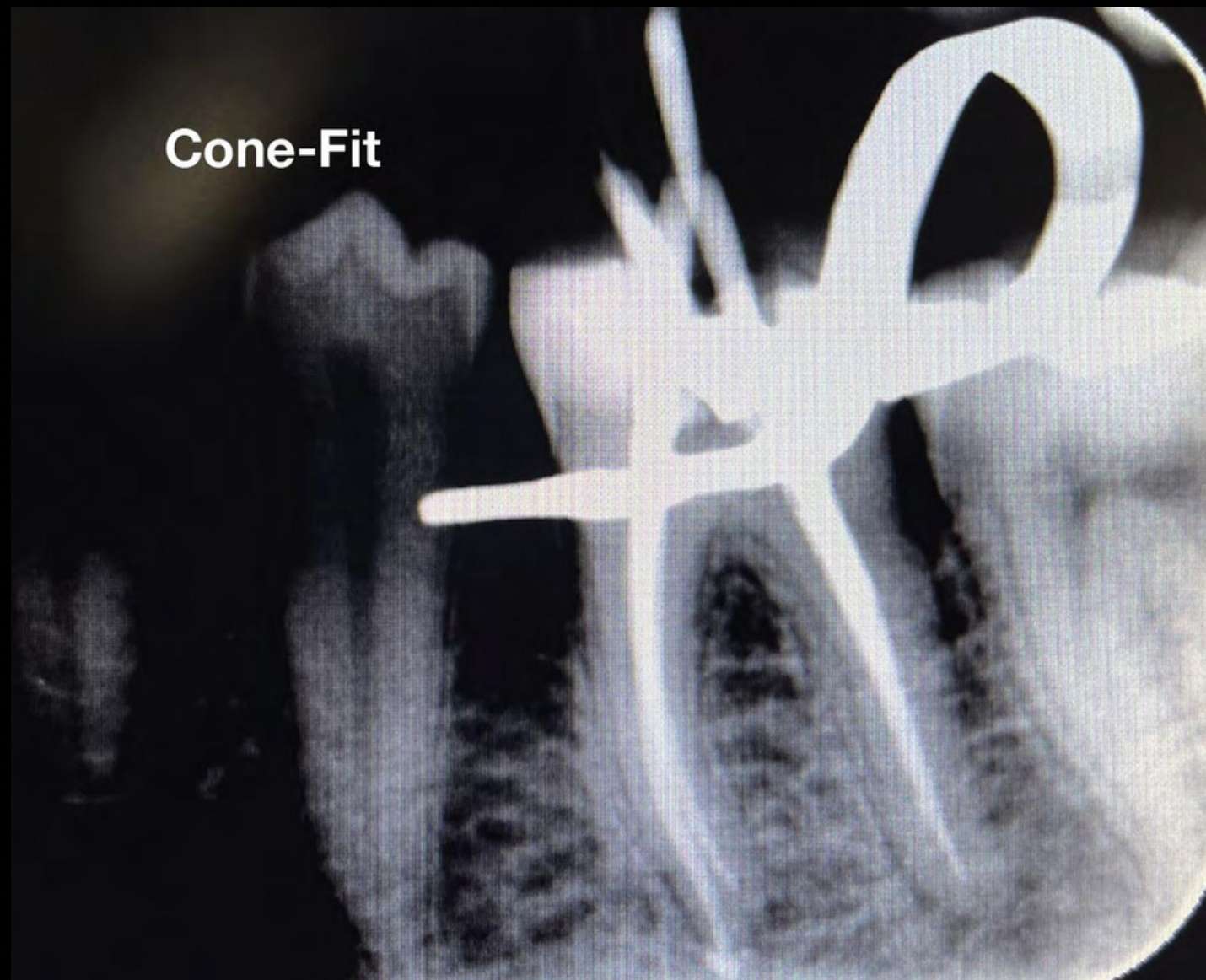
Tooth #36 was accessed, located MB, ML, and DB and DL canals. Canals instrumented with EdgeFile X7 rotary files using a crown down technique.

Endodontic diagnosis:

Pulpal Necrosis with Symptomatic Apical Periodontitis.

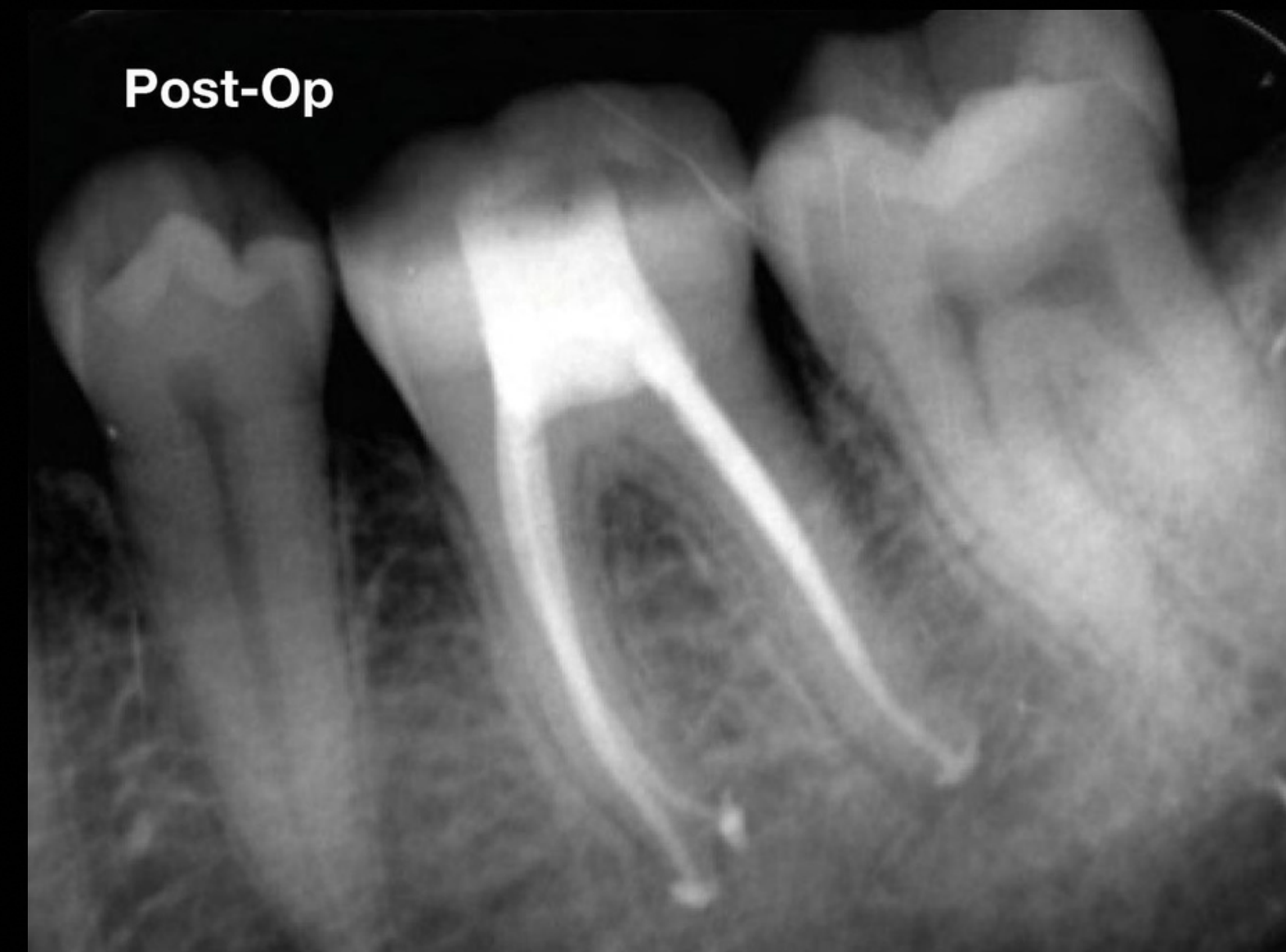

Post Obturation



Working lengths were determined via apex locator followed by radiographic confirmation. The canal system was obturated with bioceramic sealer (BUSA, BC Sealer).

Final



The access was immediately restored with a fiber reinforced dual cure core material.

Sequence of files for 'crowndown' (with MAF sizes)

X7s 25.06 to resistance, then 20.06 to resistance, then 25.06 to resistance. Working length hand file to 15, 17.04 if necessary, 30.04, 35.04, 40.04. For this case, my final rotary file was a 40.04 at 500 RPM and 2.6 N/cm torque.

Clinical Case

2

CLINICAL MANAGEMENT OF HIDDEN APICAL CURVATURES

In the great majority of cases apical curvatures are distally oriented and easily visible in a traditional 2D periapical radiographs. However, in some cases endodontists may suspect (i.e. files do not progress easily) or sometimes detect (by CBCT or using Clark's buccal object rule) hidden abrupt curvatures with different orientations. In such cases the advice is to use very flexible, fatigue resistant, martensitic files (in the present case we used EdgeEndo X7 size 17 and 25 taper. 04), with reduce bounce-back effect to reduce the risks of ledges or apical transportation.



Gianluca Gambarini, University of Rome, La Sapienza, Dental School; Director of Master of Endodontics

Alessio Zanza, Sapienza University of Roma

In these narrow apical curvatures X7 rotary instruments can be used with a clockwise reciprocating motion (150°-30°) to increase resistance to torsional stress. Otherwise, when using continuous rotation, recommendation is to slightly reduce the safety torque limits. By doing so, we improve both torsional and flexural resistance, and safely manage these dangerous hidden abrupt curvatures.

Case Report

A 65 year old patient was referred for endodontic treatment of her second lower molar (#37). She reported a history of spontaneous pain, swelling and dental fistula. Proceeding pulp vitality tests and radiographic examination, the tooth was diagnosed with symptomatic apical periodontitis.

Looking at this pre-operative radiograph, two information regarding this endodontic case should be detected (Fig.1):

Obliterated pulp chamber and narrow canals

The non-conventional anatomy of distal root

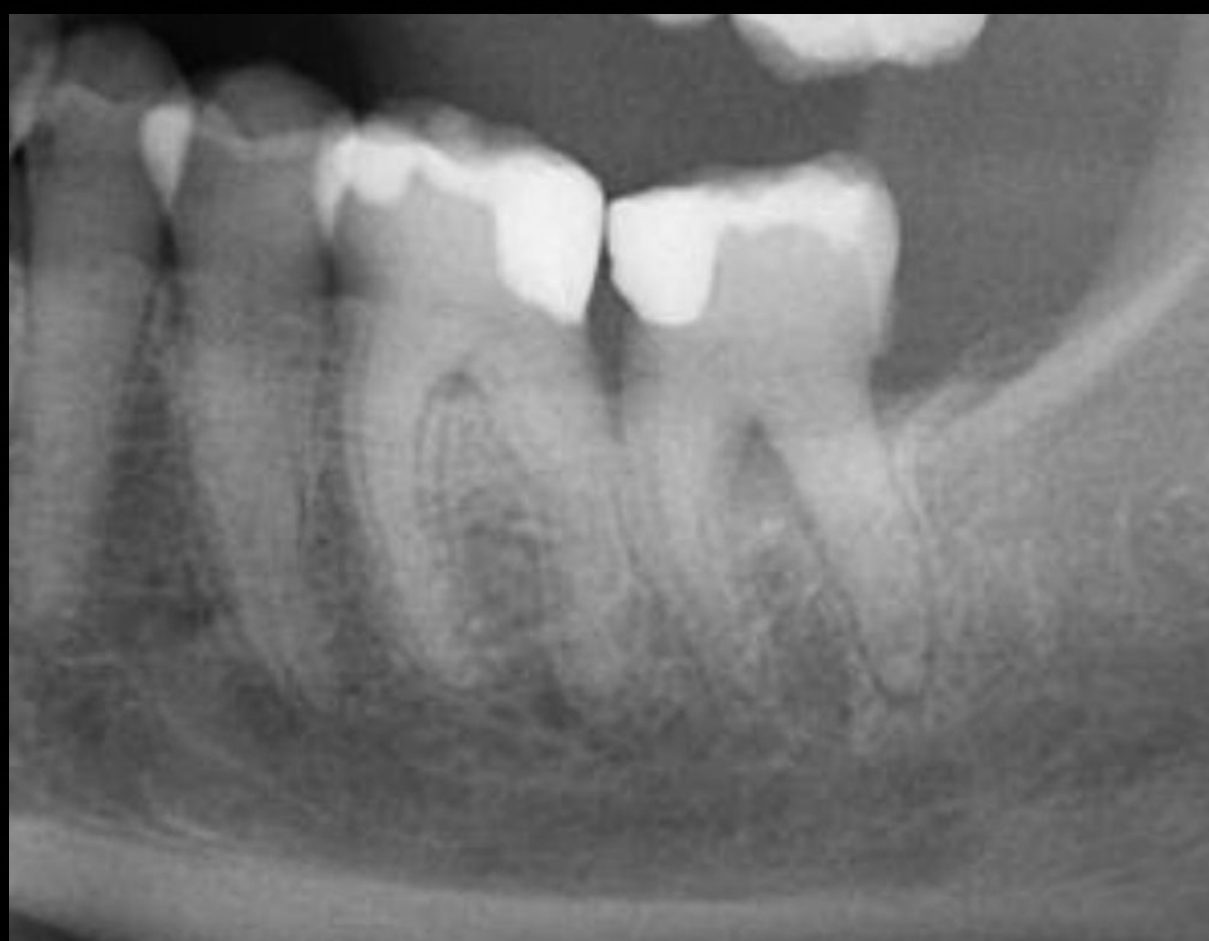


Fig.1

A traditional cavity access was performed using high speed diamond burs and the three orifices were localized with ultrasonic tips. K-file #08 was used to scout endodontic system of all roots, although it could not reach the apex in the distal canal. Pre-flaring and middle third instrumentation were gained with EdgeOne (EdgeEndo, Albuquerque, NM) reciprocating small (yellow) file, used with pecking strokes of 1-2mm, alternating with some brushing action to coronally flare canals. Frequent and copious manual irrigation was performed using solutions 5% sodium hypochlorite. Followed shaping of coronal and middle part, WL was determined with K-File #10 and shaping procedure were completed with martensitic X7 (EdgeEndo, Albuquerque, NM) instruments in sizes 17 and 25, .04 taper. The instruments were used with a reciprocating motion (150-30) to increase resistance to both torsional and flexural stress (fig.2)

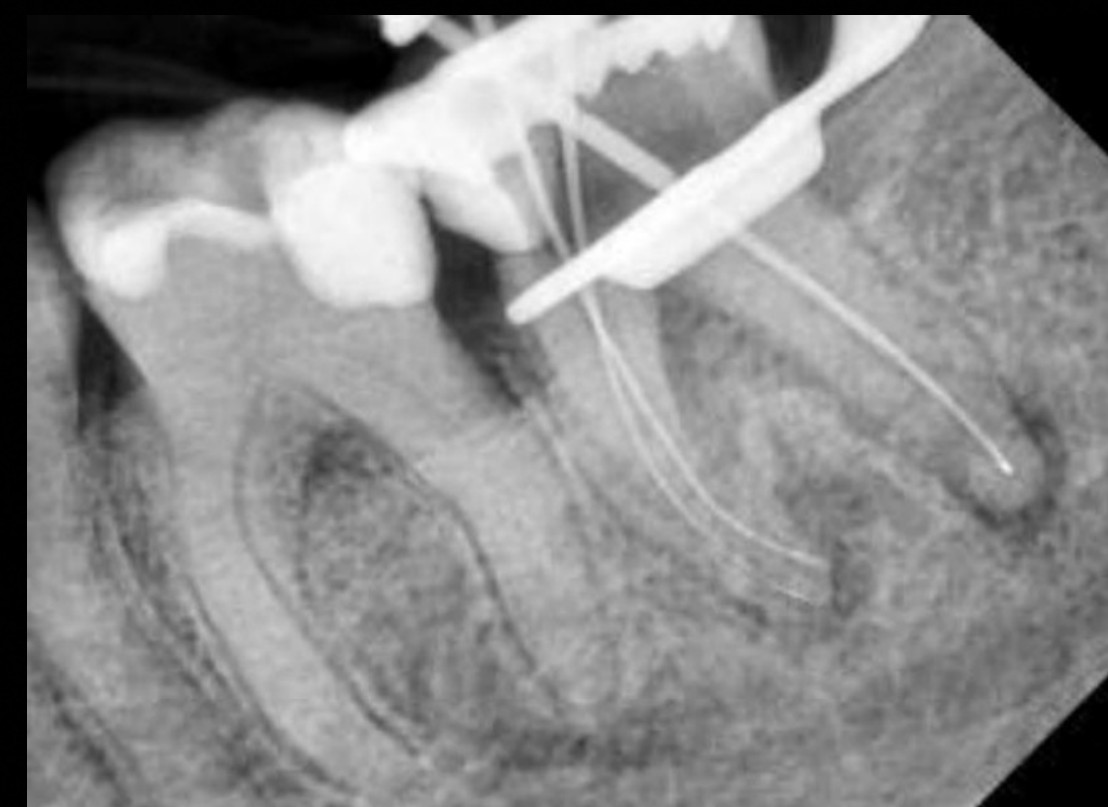

Fig.2

Final irrigation was performed activating first an EDTA solution for 1 minute using sonic activation, followed by 1 min sonical activation of NaOCl.

The root canal system was rinsed, dried and then obturated with an hydraulic single cone-technique and bioceramic sealer (BUSA, BC Sealer). Two periapical radiographs with different angulations were taken to verify treatment quality (Fig.3-4).

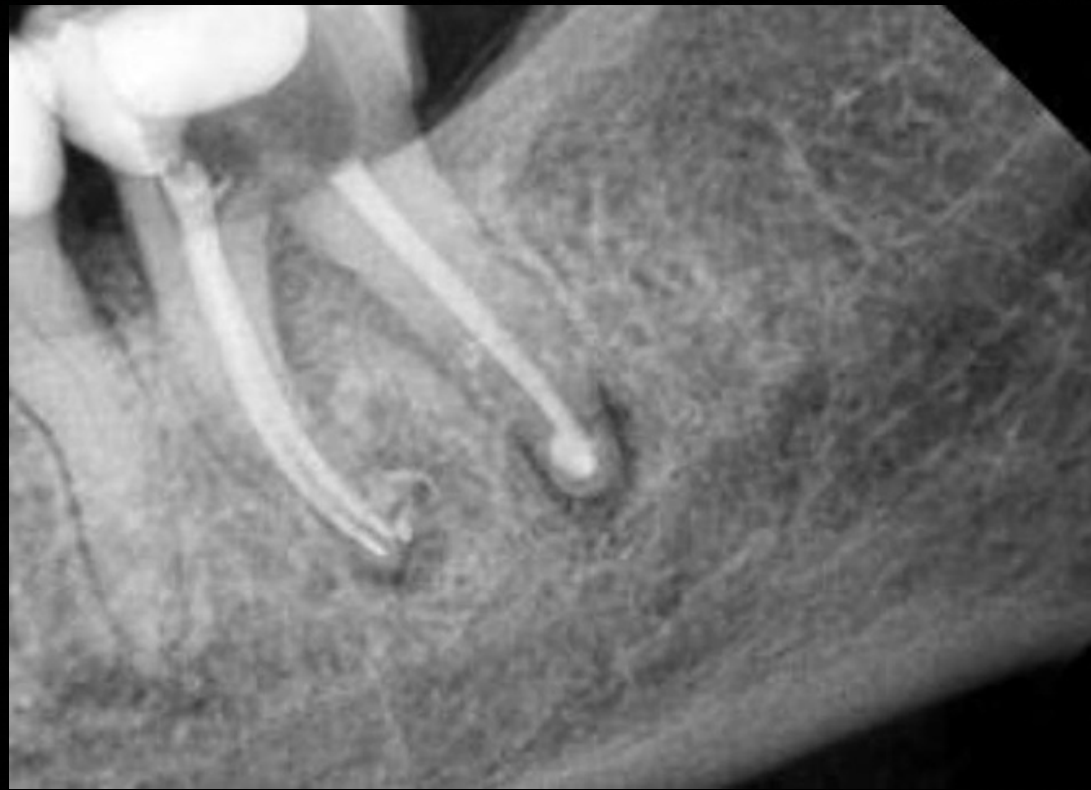

Fig.3

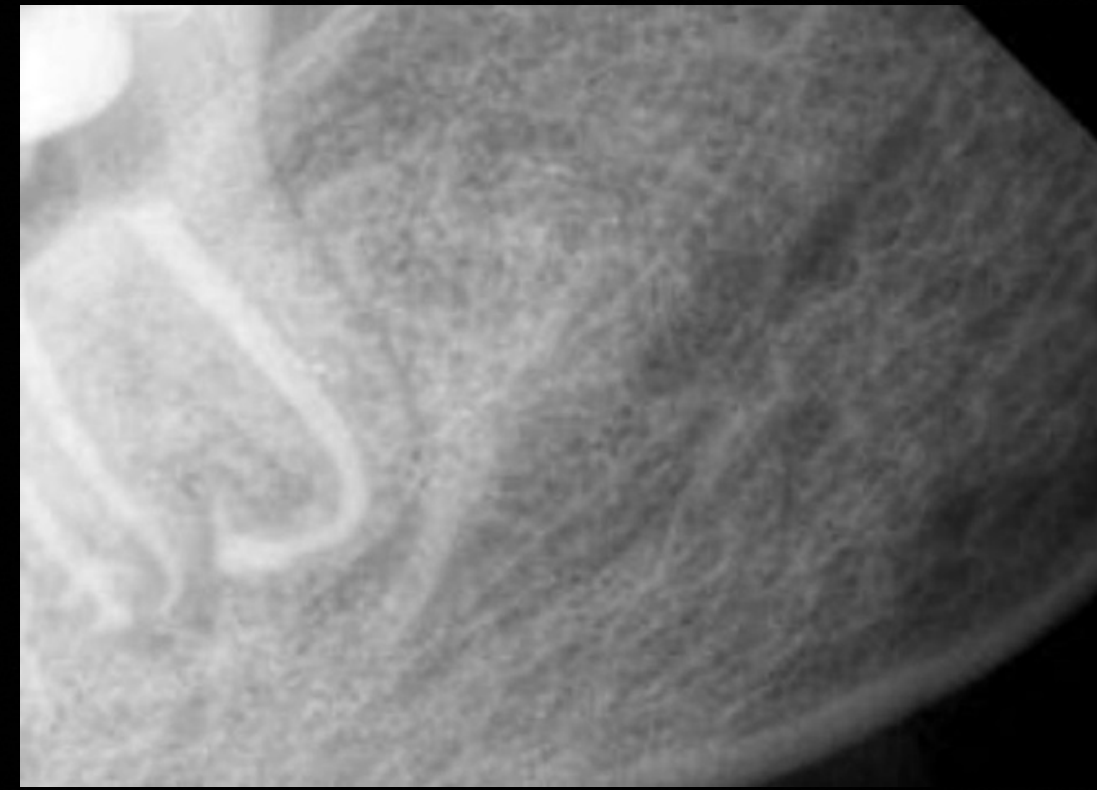

Fig.4

Clinician's suspect of unusual anatomy of the distal root anatomy was confirmed by the angulated radiograph that showed an abrupt hidden curvature in the apical third of the canal. Nevertheless the crown-down approach (shaping the coronal and middle part first, thus reducing coronal interferences) and the

proper selection of very flexible and resistance instruments, combined with a safer reciprocating clinical motions, allowed to properly negotiate the hidden curvature with no iatrogenic errors. The X7 instruments were chosen because their innovative manufacturing process which provides them with unprecedented flexibility and resistance to cyclic fatigue, allowing practitioners to perform procedures that would be difficult, if not unimaginable, with traditional non-heated files. More precisely, EdgeEndo has focused research and development in the heat-treatment of NiTi files and has developed a proprietary process to produce FireWire™ files that exhibit 2 to 8 times the resistance to cyclic fatigue (and flexibility) than other NiTi files. The benefits of a flexible file seem obvious in complex curvature, but martensitic X7 files

also offer another advantage: less "shape memory". Although shape memory may seem beneficial, it can cause a file to "bounce back" in the tooth, putting lateral pressure on the canal wall, potentially leading to canal transportation or ledging. The present case shows how the excellent clinical performance of X7 files in a very complex anatomy, by avoiding the above mentioned, common iatrogenic errors.

Clinical Case

3



EDGEENDO®



– **James A. Wealleans, D.M.D**, American Board Certified Endodontist, Adj Professor, Clinician Sydney, Australia

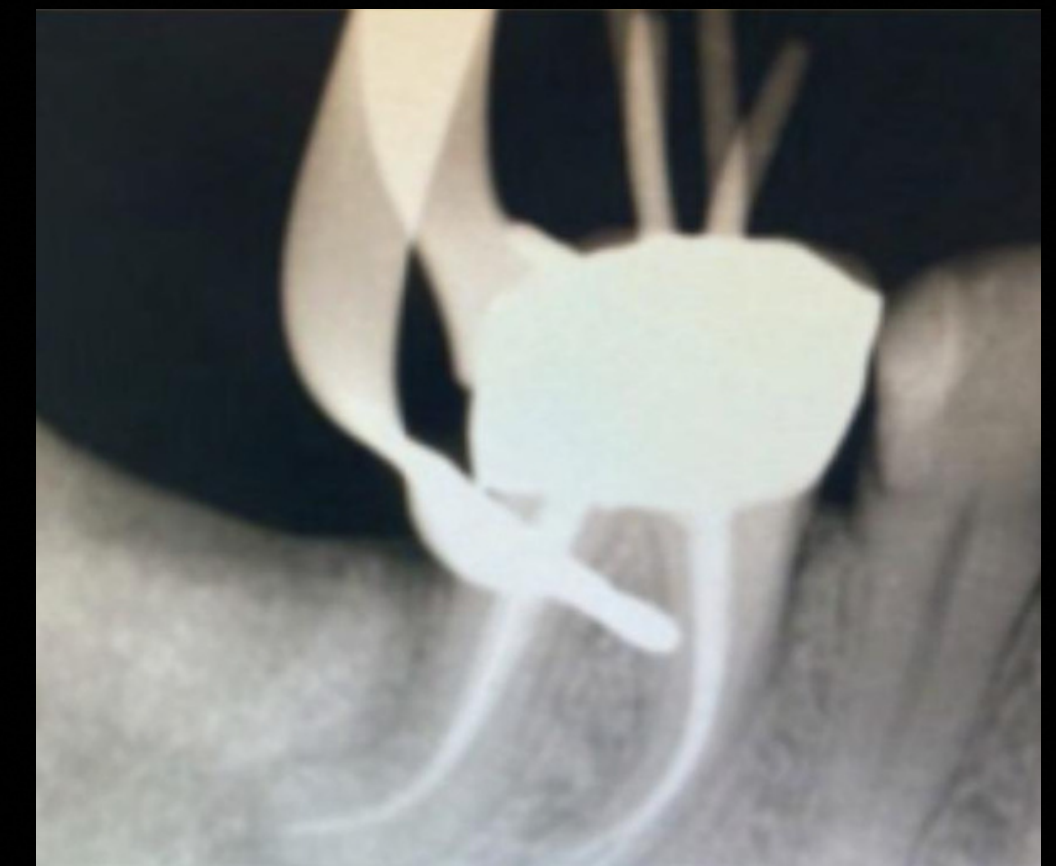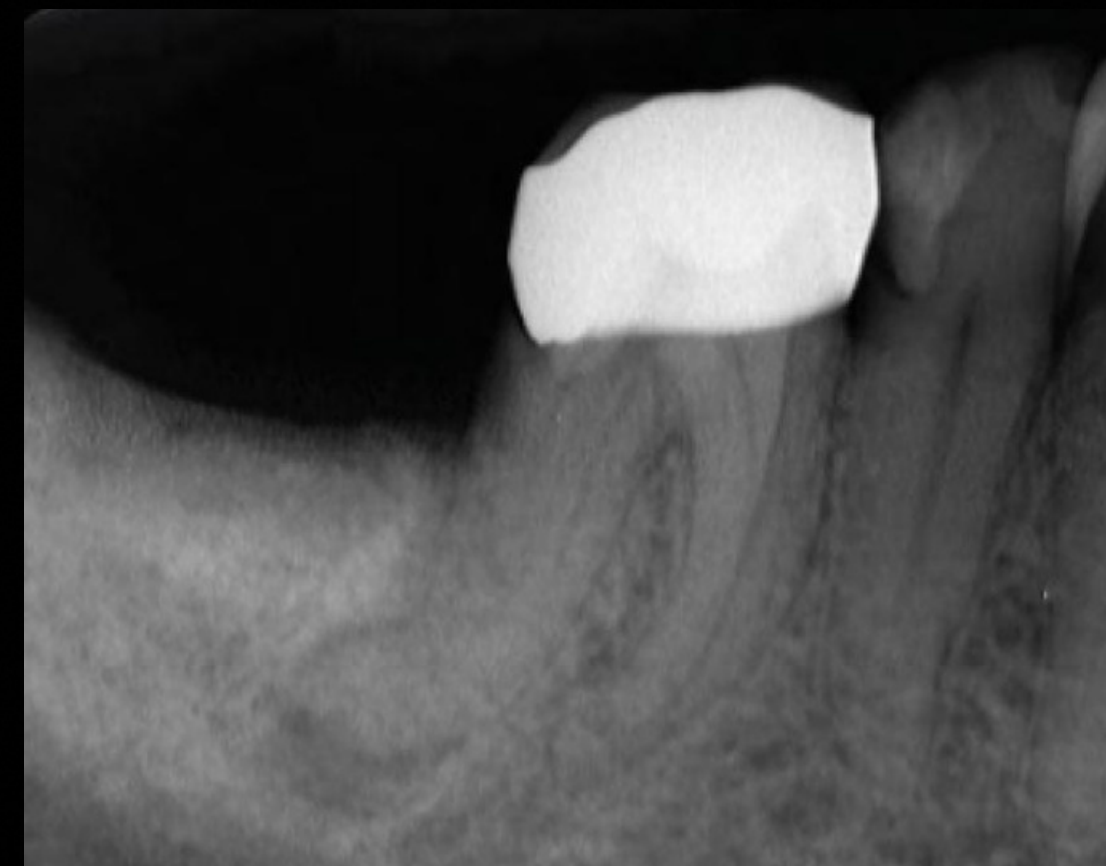The patient was referred to our endodontic practice for evaluation and treatment of tooth 46. Clinically #46 had an all-ceramic crown, a negative response to cold, and tenderness to percussion. Pre-op x-ray revealed #46 had a periapical radiolucency associated with the Distal root and severe D root curvature in the apical third.

Endodontic diagnosis:

Pulpal Necrosis with Symptomatic Apical Periodontitis.

Pre-Op

Tooth #47 accessed, located MB, ML, and DB and DL canals. Canals instrumented with EdgeFile X7 rotary files using a crown down technique



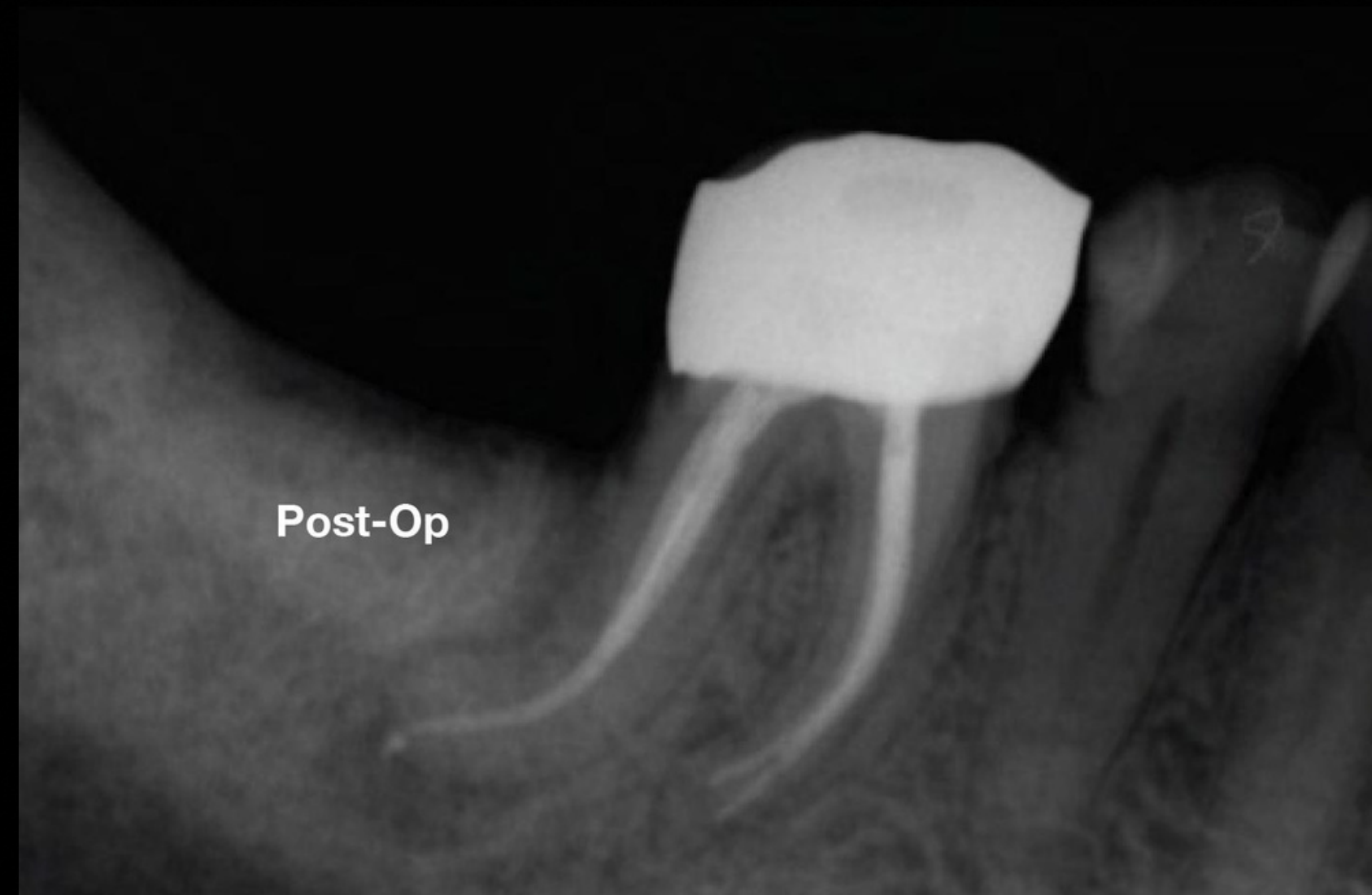
Cone-Fit

Working lengths were determined via apex locator followed by radiographic confirmation. The canal system was obturated with bioceramic sealer (BUSA, BC Sealer). The access was immediately re-stored with a fiber reinforced dual cure core material.

Sequence of files for 'crowdown' (with MAF sizes)

EdgeFile X7 25.06 to resistance, then 20.06 to resistance, then 25.06 to resistance. Working length hand file to 15, 17.04 if necessary, 30.04, 35.04, 40.04.

For this case, I vigorously used hand files above my typical sequence to a #35K and finished with an X7 35.04 at 500 RPM 2.6 N/cm torque.

**“**

EdgeEndo are hands down the best rotary instruments on the market! The flexibility and durability are unmatched! It was a seamless transition to switch and file separation became a thing of the past! ”

– **James A. Wealleans,**
D.M.D., American Board Certified
Endodontist, Adj Professor,
Clinician Sydney, Australia



ENDODONTIC CASE REPORT HYBRIDIZING HEAT TREATMENTS TECHNIQUE

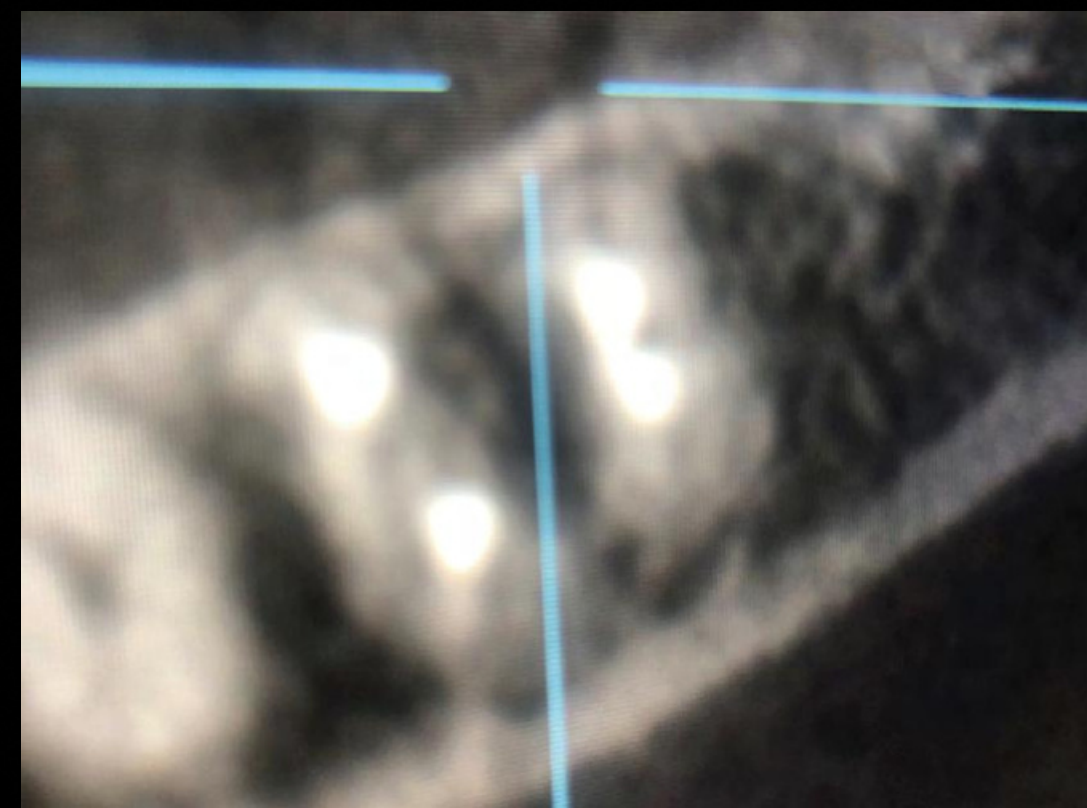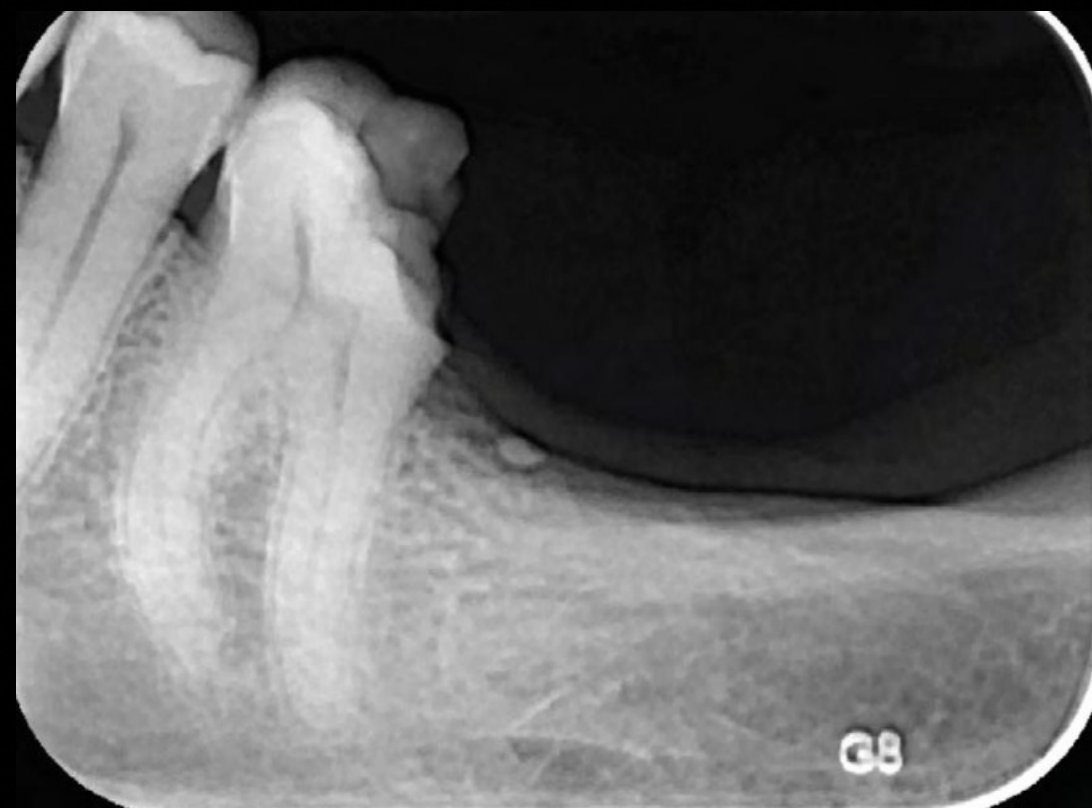A 42 year old female patient came to the office complaining about crown fracture and severe pain in the left mandibular posterior area. Intraoral and radiographic examination revealed disto-occlusal decay in tooth 3.6, and exposure of the distal pulp horn. Tooth was highly sensitive to thermal cold test; an acute pulpitis was diagnosed and an endodontic orthograde treatment was proposed and accepted. Following a minimally invasive approach, access cavity was designed starting from the distal portion of the tooth, to avoid unnecessary loss of dentinal structure. Such a decision was a compromise between the advantages provided by a wider, straight line access (which is ideal in complex narrow curvature like in the present case) and the disadvantages from weakening the residual tooth structure: the mesial marginal ridge was intact, and it was decided to preserve it according to minimally invasive endodontic




Prof. Gianluca Gambarini

protocols. Moreover, an ideal straight-line insertion of endodontic nickel-titanium (NiTi) rotary instruments is not always possible when a molar is slightly distally inclined, like the present case. More complex root canal configurations (i.e. when additional canals are present like in this case) require more attention in planning adequate endodontic access to properly reach all the different orifices.

As a consequence, clinician was aware that NiTi rotary instruments would have been subjected to high flexural stress, due to the presence of multiple curvatures, which also required flexibility to be negotiated with no iatrogenic errors. Therefore, the first parameter was the selection of extremely flexible, heat treated, controlled-memory martensitic NiTi instruments; the second one was the selection of instruments with variable tapers to minimize taper-lock and screwing-in effect; the third parameter was the selection of instruments with enough metal mass to withstand torsional loads in narrow canals. The choice was in favor of EdgeTaper Platinum (ETP) by EdgeEndo, Albuquerque, NM, which provided all the required features; very resistant and flexible instruments, which can be deformed more easily than competitors' file and maintain the given precurvature, allowing an easier insertion and minimizing the need for a wider access cavity.



After a manual glide-path with stainless steel K-files up to size 15, and working length determination with an electronic apex locator, ETP instruments were used with the following sequence: S1, S2, F1, F2. All instruments reached the full working length, gently rotated at 300 rpm (and 2N torque), avoiding overloading. Two crucial operative parameters were chosen; first, during inward motion, instruments progressed slowly, in steps (not more than 1-2 mm progression for each step) and after each step they were removed from canals, the flutes were cleaned and syringe irrigation performed. Such a careful progression allowed to avoid excessive friction due to wider blade engagement and reduced debris inside the flutes. Moreover, debridement was enhanced with more frequent irrigation, and less production of debris.



“

Quality and price are number one feature, and I have never had a file break on me.

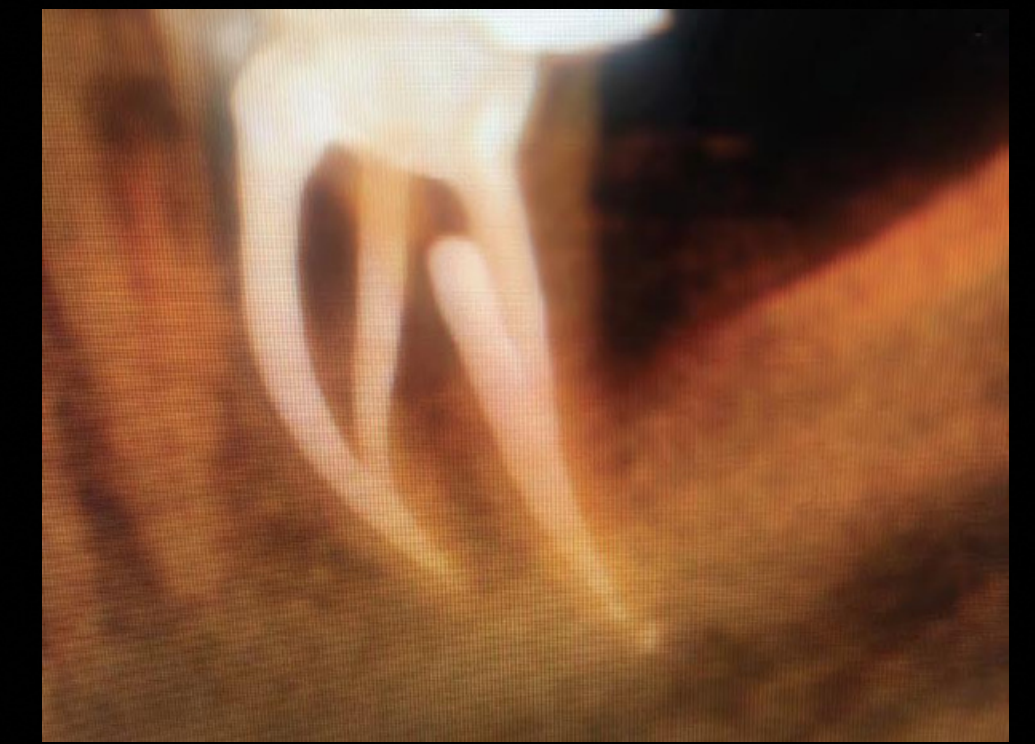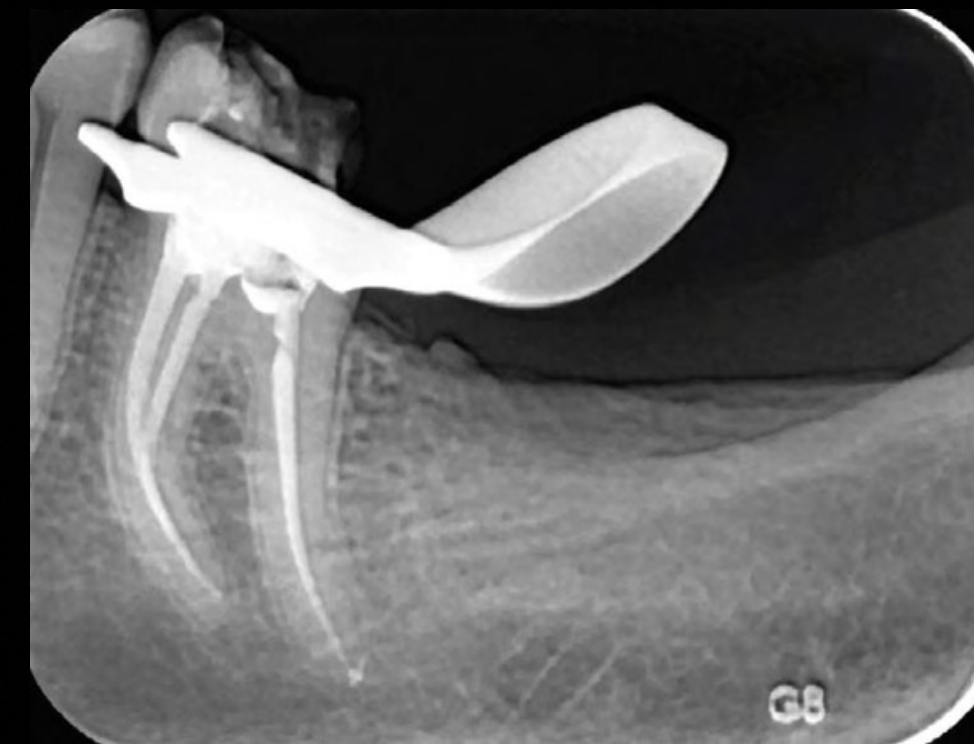”

– **Dr. William E Judson**, D.D.S., Family and General Dentistry, El Sobrante, CA, USA

The second parameter was the use of outward motion to improve coronal flaring. This could have been done with the same ETP instrument, but for the S1 and S2 instruments slightly more rigid EdgeTaper (ET) rotary instrument were chosen. ET instruments have same design of ETP but no heat treatment, which makes them a bit more stiff and efficient in cutting. Therefore, ET S1 and S2 (used after ETP S1 and S2, respectively) allowed a more rapid and valid coronal flaring. They were used only with an outward motion (“brushing”), an increased speed (500 rpm) and reduced torque (1.5N). By eliminating coronal interferences and increasing canal diameters ET S1 and S2 made apical preparation with ETP F1 and F2 quicker and safer, as shown in the CBCT images (fig.2 and 3). Outward motion was found to be extremely safe, with minimal torsional and flexural loads on the NiTi rotary instruments, provided that the instruments are never fully engaged or blocked inside canal. This new, innovative combination of similar instruments (ET and ETP) with different properties related to a different manufacturing process, is called “hybridizing heat-treatments technique” and was nicely performed using the above-mentioned instruments.



Figures 3 and 4 show how canal trajectories were nicely maintained, and proper shaping (adequate canal diameters can be better appreciated in 3D images, as shown by fig. 2 and 3) was quickly and simply performed in a 45-minute single-visit root canal treatment, with no iatrogenic errors, no instruments' deformation or fracture. Canals were obturated with a single cone cold hydraulic technique using bioceramic sealer (BUSA, BC Sealer), a material that provides a simple and fast solution.



Clinical Case

5



EDGEENDO®

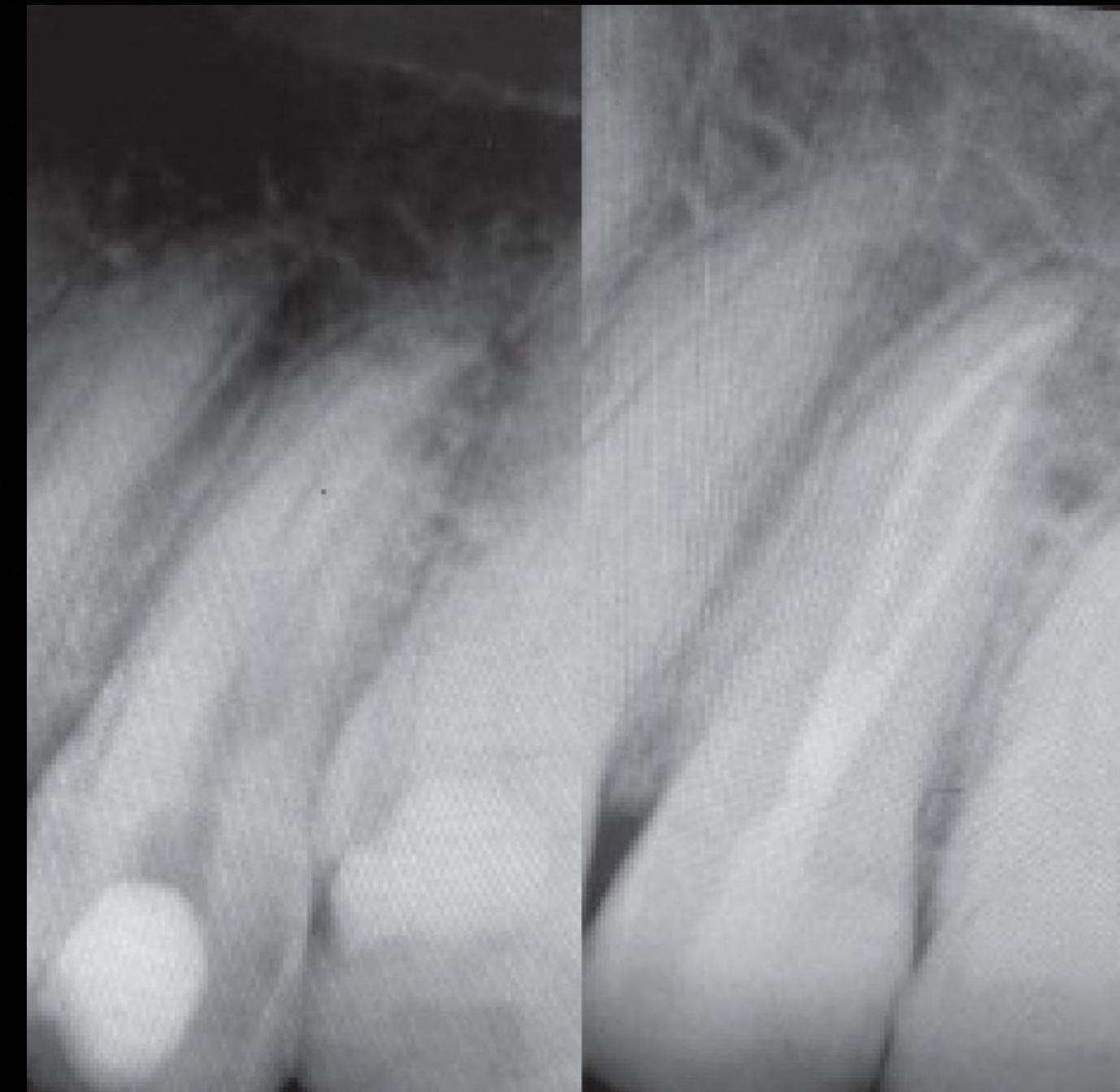


Sean Sunyoto, DDS

In my experience, many endodontic files are prone to unwinding—that is, with the exception of the EdgeOne Fire. While I previously used files from another leading endodontic manufacturer, switching to EdgeEndo's NiTi reciprocating files has allowed me to provide safer, more effective endodontic treatment. The instruments in this advanced 4-file system are flexible and durable, which reduces root canal treatment time, while the Glidepath for EdgeOne Fire, in particular, gives me sufficient access for effective irrigation. The following case demonstrates how the premium technology built into EdgeEndo files helps me easily navigate canals and achieve successful outcomes.

This case was referred to me by a doctor who was unable to negotiate his patient's tortuous, ledged, and calcified canals, possibly because he did not have the ideal instruments for the case. During treatment, I negotiated the patient's canals to apex using my #8 and #10 files. From there, I used EdgeGlidePath by EdgeEndo, which performs ideally in tight canals. When it began to bind after 1–2 mm, I paused to irrigate the area, recapitulated with my #10 file, and reentered with the EdgeGlidePath file to length.

Thanks to the flexibility and ease of use offered by EdgeOne Fire files, I completed this root canal rapidly and safely. Preop and postop images taken 4 months apart display signs of successful healing and an absence of a fistula. I think these files are great tools that every clinician should have.



Preop vs. Postop
Radiographs taken
4 months apart

Clinical Case

6



EDGEENDO®

The following case study was transcribed from a Skype interview and republished with permission from Dr. Yanina Figueroa.

I haven't received any endorsement... but this is the only file that could tackle that case.

**– Dr. Yanina Figueroa,
Endodontist, Endodontics
of Cobb, Atlanta, GA. USA**



Dr. Figueroa Tames, Endodontist,
Endodontics of Cobb, Atlanta, GA. USA

A Passion for Endodontics

When colleagues ask her why she decided on Endodontics as a specialty, she responds, "I love the challenge, every person and tooth is different. There is never a dull moment just a dull bur!"

Dr. Yanina Figueroa's sense of humor is as sharp as her skills. We understood that after only a few minutes of talking with her.

Growing up in Puerto Rico, she attended public high school, obtained a bachelor's degree of science in Biology from the University of Puerto Rico-Mayagüez Campus in 2003, and received her D.M.D from the University Of Puerto Rico School Of Dental Medicine in 2007. During her post-graduate years she developed a passion for Endodontics while working as a general Dentist in private practice. Dr. Figueroa materialized her dreams by completing her training in Endodontics in 2013 from The University of Pennsylvania. There she was trained utilizing the newest technology and following the University of Pennsylvania Vision of Excellence in Endodontics.

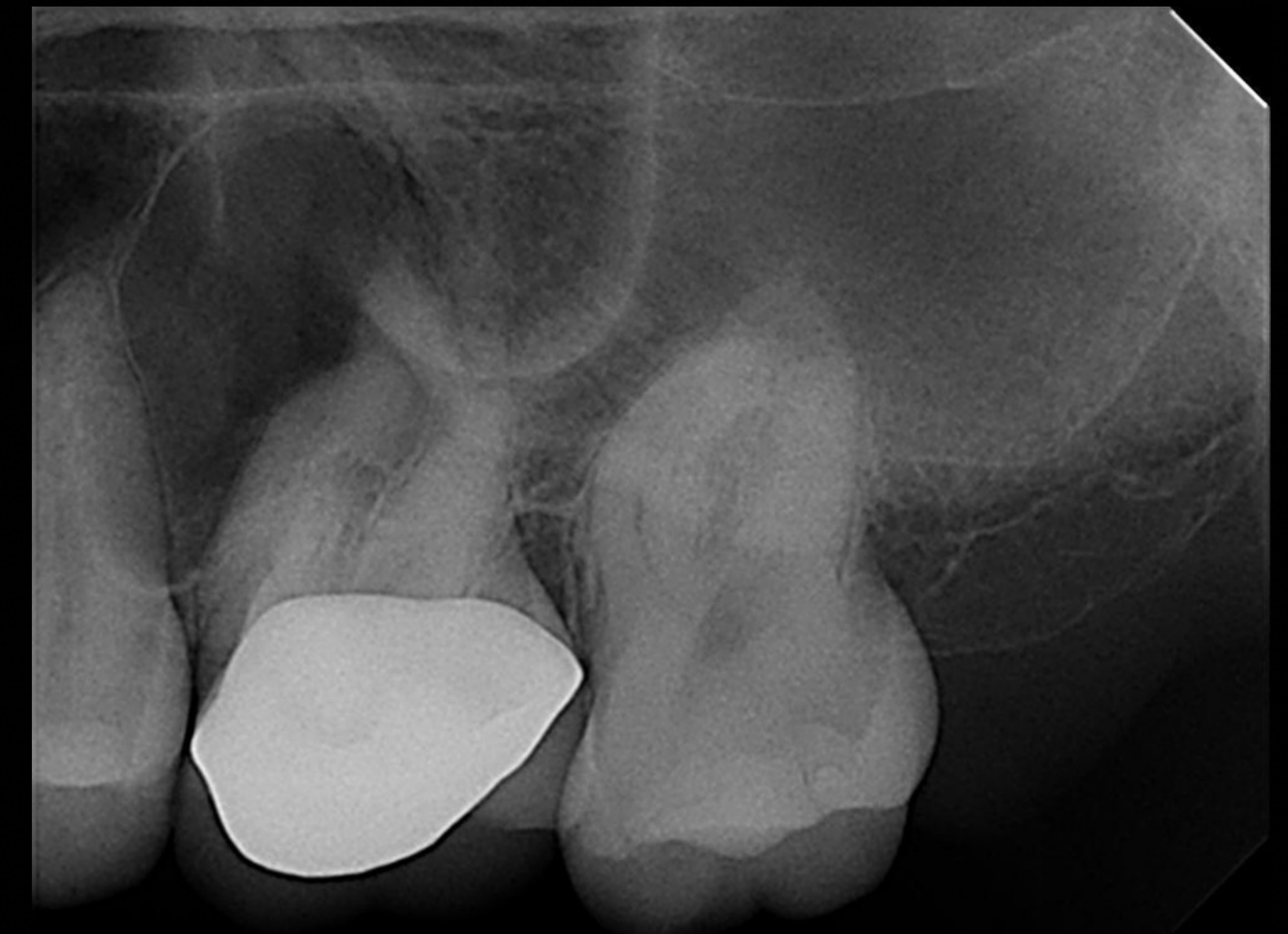


EDGEENDO®

Beastly Bifurcation by Dr. Yanina Figueroa

I'm an endodontist from Atlanta, Georgia, and I did my specialty at the University of Pennsylvania, graduated 2013 and I wanted to share with you this case of a molar number 14 of a 33 year old patient with irreversible pulpitis and Symptomatic Apical Periodontitis. This case was diagnosed and accessed through the crown using diamond burrs. Then, irrigation with sodium hypochlorite.

When you see a case like this, you're wondering to yourself, what file am I going to use for this? How am I going to negotiate that canal without having file breakage?



Dr. Yanina Figueroa's "Beastly Bifurcation," was featured in the April 2015 DentalTown issue.

We met her when we connected with her on our EdgeEndo® Facebook page. In her constant quest to find the newest and best instruments to tackle her challenging cases, Dr. Figueroa was one of the "early adopters" of the heat-treated EdgeFile®. She is such a fan that she and her "Beastly" case were featured in an EdgeEndo® advertising campaign.

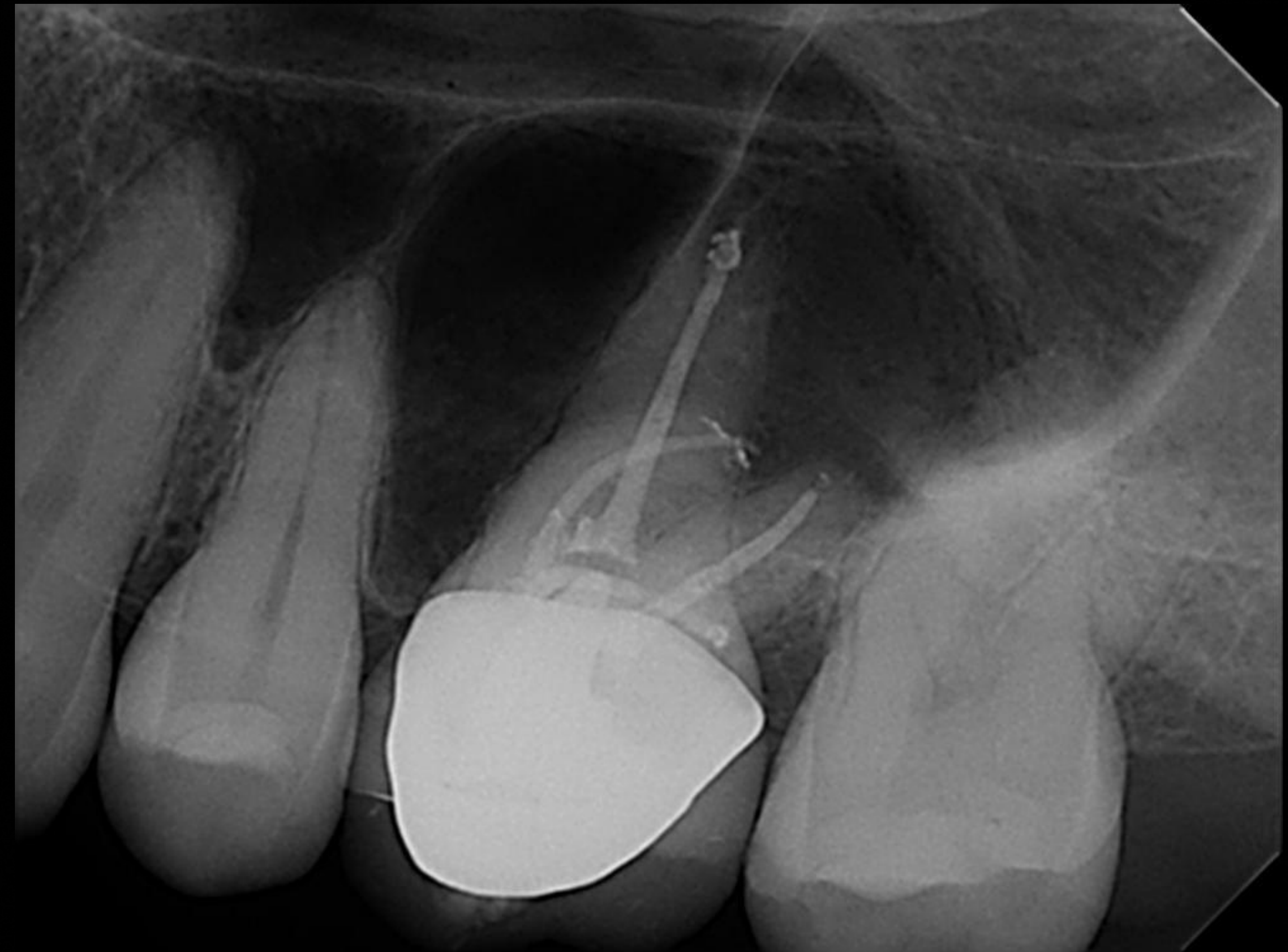


First, I tried to get patency of the canals, I did the patency of the distal mesiobuccal canal and distal canal using 10 files, and then worked my way up to a 15 file. I instrumented this case using an SX file to open the orifices, then used copious irrigation with sodium hypochlorite.

I started using the EdgeEndo files utilizing crown down technique, when you see these type of canals that are very curved, you want to flare up a little bit the upper portion of the canal, so your files can slide down easier and have less binding on the walls. I started doing the crown down from a 40 to a 25 and then went all the way to 40's on the mesiobuccal, on the distal, and I did the palatal to a 45.

**I went to a 40 on that root...
any other file would have just
broken and just could have
been impossible to retrieve.**

When I took the x-ray to see how the cones were fitting, I noticed that there was a canal missing, so I used the CBCT to find the MB2 canal. All this, of course, while I'm using my EdgeFiles, I used also lube, RC prep for the instrumentation, and I also used a lot of sodium hypochlorite to instrument. Before doing the cone fit, I do irrigation with ultrasonics using sodium hypochlorite, EDTA, and chlorhexidine. I did my cone fit with the Edge Gutta Percha and the AH Plus sealant.



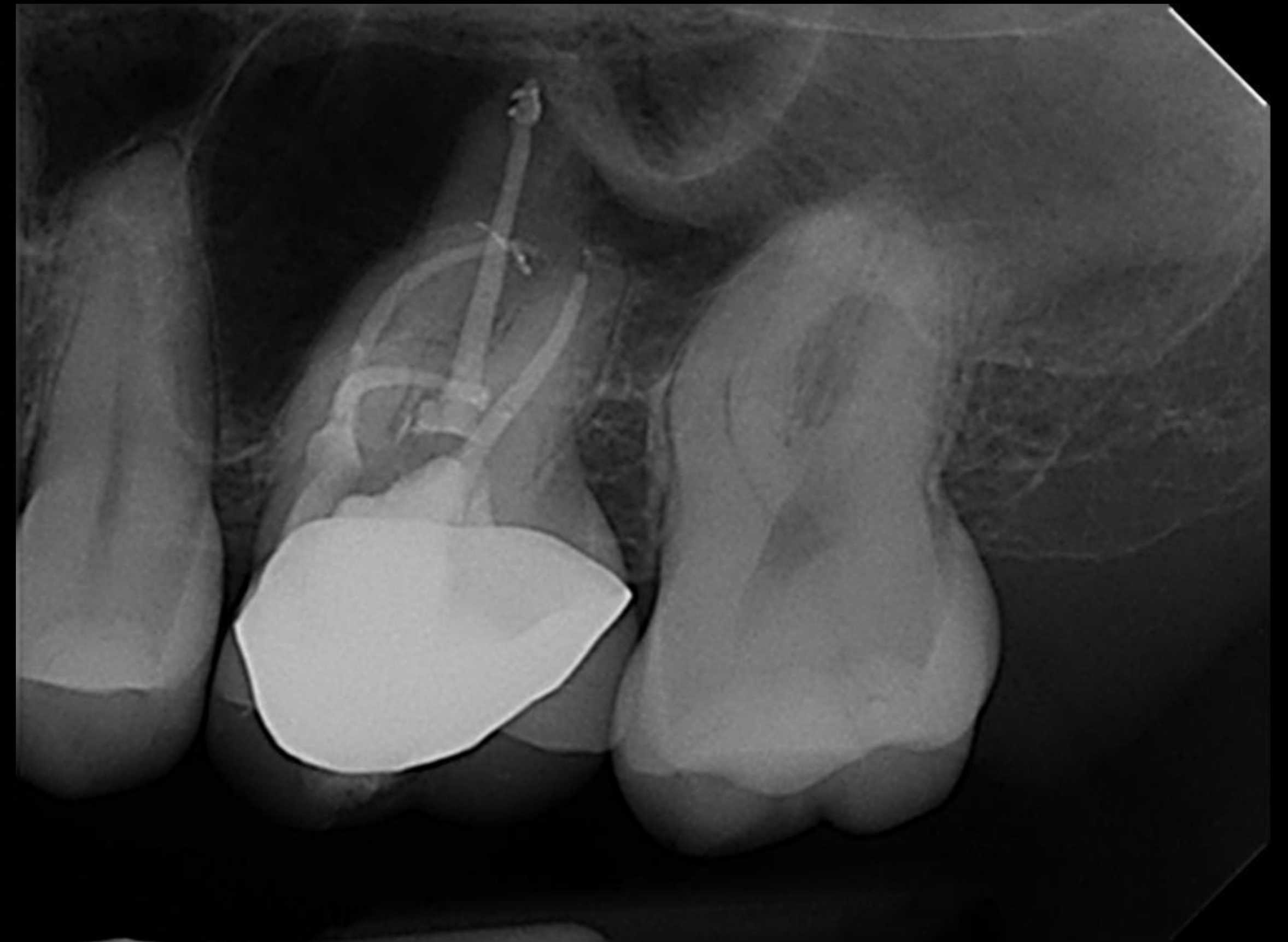


EDGEENDO®

When I took the x-ray to see how the cones were fitting, I noticed that there was a canal missing...

Now, I can tell you when I took the x-ray I saw that the MB2 was missing, so I took a CT scan and noticed the MB2 and noticed the weird unusual buccal inclination of the MB2 to the palate, and the MB really pointing towards the buccal. It looked almost like a snake tongue. I was like, oh wow, this has been the thing that I was looking for. I found the MB2 on the second visit. I closed everything up before that with calcium hydroxide, then on the second visit I found MB2.

I proceeded to do the instrumentation up to a 35 on MB2 with the same sequence, using sodium hypochlorite, first of all going up to a number size 15 and doing crown down to a 35. After that, I irrigated everything with sodium hypochlorite, EDTA, chlorhexidine, and I dried everything up with sterile paper points, and took an x-ray with the cone fitting, with cones and age plus sealant.





EDGEENDO®

I haven't received any endorsement...but this is the only file that could tackle that case.

After verifying that the diagnostic intermediate x-ray looks fine, I closed everything up using vertical condensation, just leaving 4 millimeters of the apical portion of the cone, and then back filling with Edge Gutta Percha. After that, very important, I always put an orifice barrier. I use purple permaflow orifice barrier, then I put a cotton pellet and that was that.



AAAAAAH the panacea...

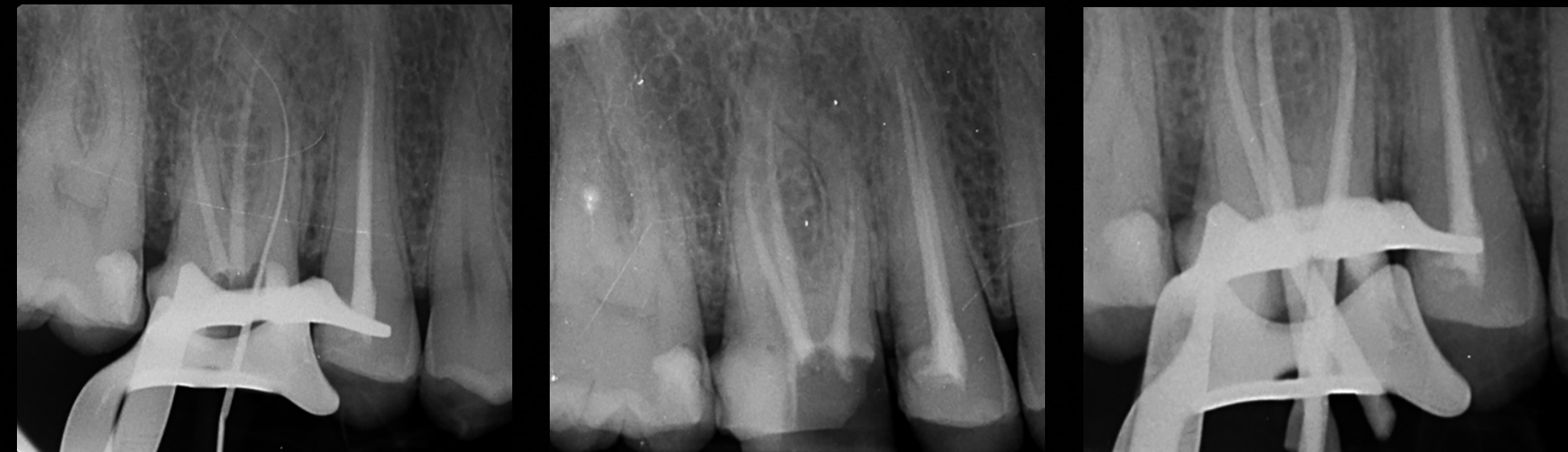
I was trained at U Penn and we believe in large apical sizes and I went to a 40 on that root... any other file would have just broken and just could have been impossible to retrieve. When I did this case I was like "AAAAAAH the panacea."

The EdgeFiles have been the best files I have used so that is why I am so excited about them.

Clinical Case

7

EDGETAPER BLAZE UTOPIA™



Case Provided by:
Maya Feghall, DDS Paris, France

Calcified curved canals

Calcified curved canals represent a real challenge in endodontic. this situation is frequent in the mesiopalatal canal of upper molars making the negotiation and the preparation of the canal difficult. Heat treated files are more flexible and resistant to flexural fatigue then traditional NiTi instruments making them the instruments of choice for preparation of complex canals.

Aim

the present case shows the clinical advantage of using heat treated files (Utopia Blaze) for the preparation of calcified and curved canals.


Case History

RTR of first upper molar with the presence of a ledge in the mesial canal. also, the roots were very long with 28mm of length in this case, after manual glidepath, the use of manual pre-banded files was necessary to manually bypass the ledge. Once the file has reacted the part after the ledge it was then coupled to the endo motor to complete the preparation of the canal. the later treatment was only possible with flexible and pre-bendable files.



**Files with Incredible
Strength &
Flexibility
Learn more**

EDGEFILE[®] X7



The revolutionary EdgeFile X7 uses our own flexible FireWire™ NiTi forged with our proprietary heat-treating process. The FireWire™ NiTi Alloy improves strength and flexibility. Best selling system.

Our heat-treating process gives the EdgeFile X7, "Canal Contouring Technology," making the files extremely flexible and reducing the shape memory and "bounce back" effect of other NiTi files. The flexible EdgeFile™ closely follows the anatomy of the canal without straightening out, reducing the risk of ledging, transportation, perforation and file separation. The flexible shaft reduces the need for excessive straight-line access, allowing more tooth structure to be preserved.

X7 is the most recognized and proven solution. It has repeatedly outperformed competitor files in peer reviewed published research.

EDGEFILE[®] X7 Features

1

Proprietary heat treatment process- FireWire™ NiTi Alloy improves strength and flexibility

2

Available in .04 and .06 Constant Taper- Variable Pitch

3

Maximum flute diameter 1mm allows for minimally invasive preparation

4

Parabolic Cross Section non cutting tip- Maximizes file cutting efficiency

5

Electropolished file - Increases strength

6

Reduced handle length for increased posterior access

7

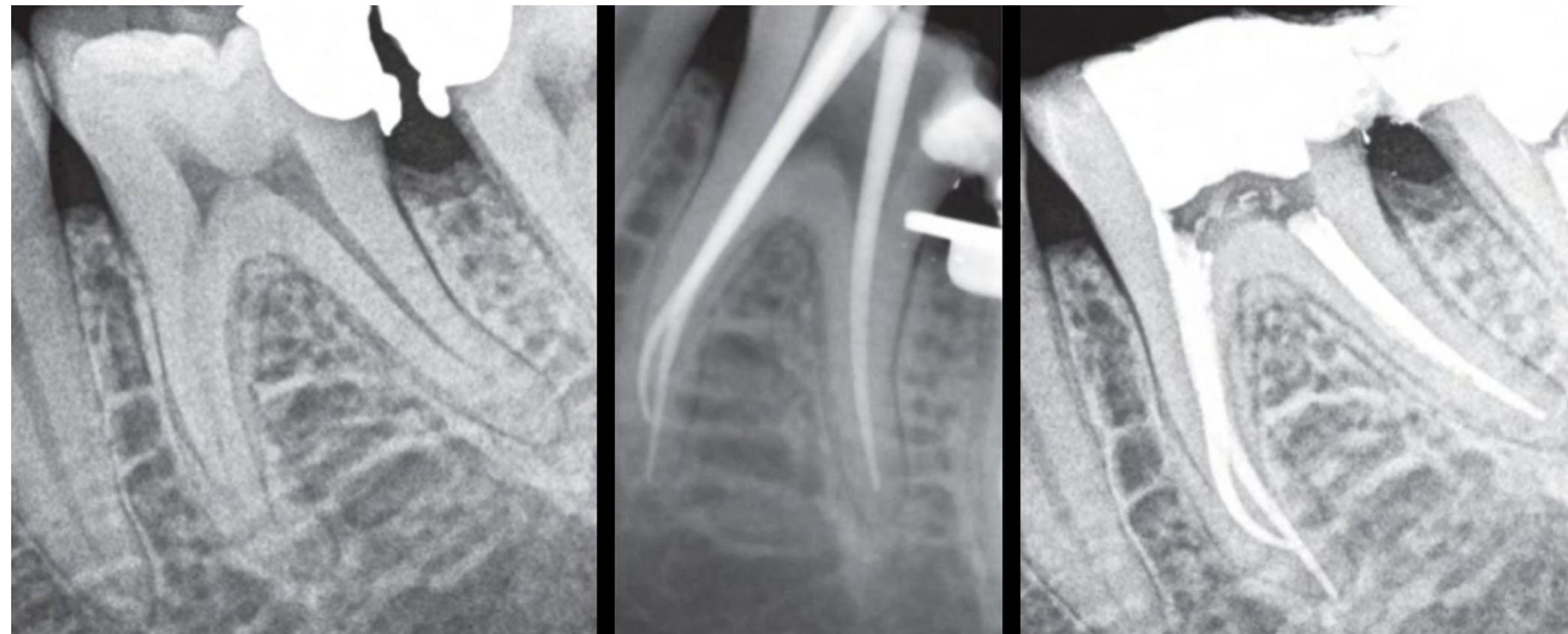
ISO tip size 17-45

8

Available lengths: 21, 25 & 29 mm

Keen to learn more?

A Novel Root Canal Preparation Technique Hybridizing Heat-treated Nickel-Titanium Rotary Instruments



Abstract

Aim

This study aimed to assess the potential of the hybrid heat treatment (HHT) technique for shaping severely curved canals.

Background:

This innovative HHT technique combines the use of both NiTi austenitic and martensitic NiTi files, with a simplified sequence, to properly utilize the different files' properties.

Case description:

The operative technique started with canal scouting and determination of working length using a size 10 SS K-file. Then, a specific sequence was applied using the F1 20.06v Ni-Ti austenitic file (EdgeTaper) for the preparation of the coronal and middle parts of the canal. This step was followed by S2 20.04 and F120.06v martensitic Ni-Ti files (EdgeTaper Platinum) to enlarge the canal until the apex reached. No intracanal breakage of any instruments or deformation of flutes was recorded.

Conclusion:

The present study describes a new HHT technique aiming at simplifying procedures and taking most of the different characteristics of the different heat treatment; the clinical cases seem to show its potentialities in terms of safety, speediness, effectiveness, and preservation of original anatomy.

Clinical significance:

The cases show the advantages of the newly proposed technique over a traditional approach to properly shape complex anatomies with only a few Ni-Ti rotary instruments number.

Keywords:

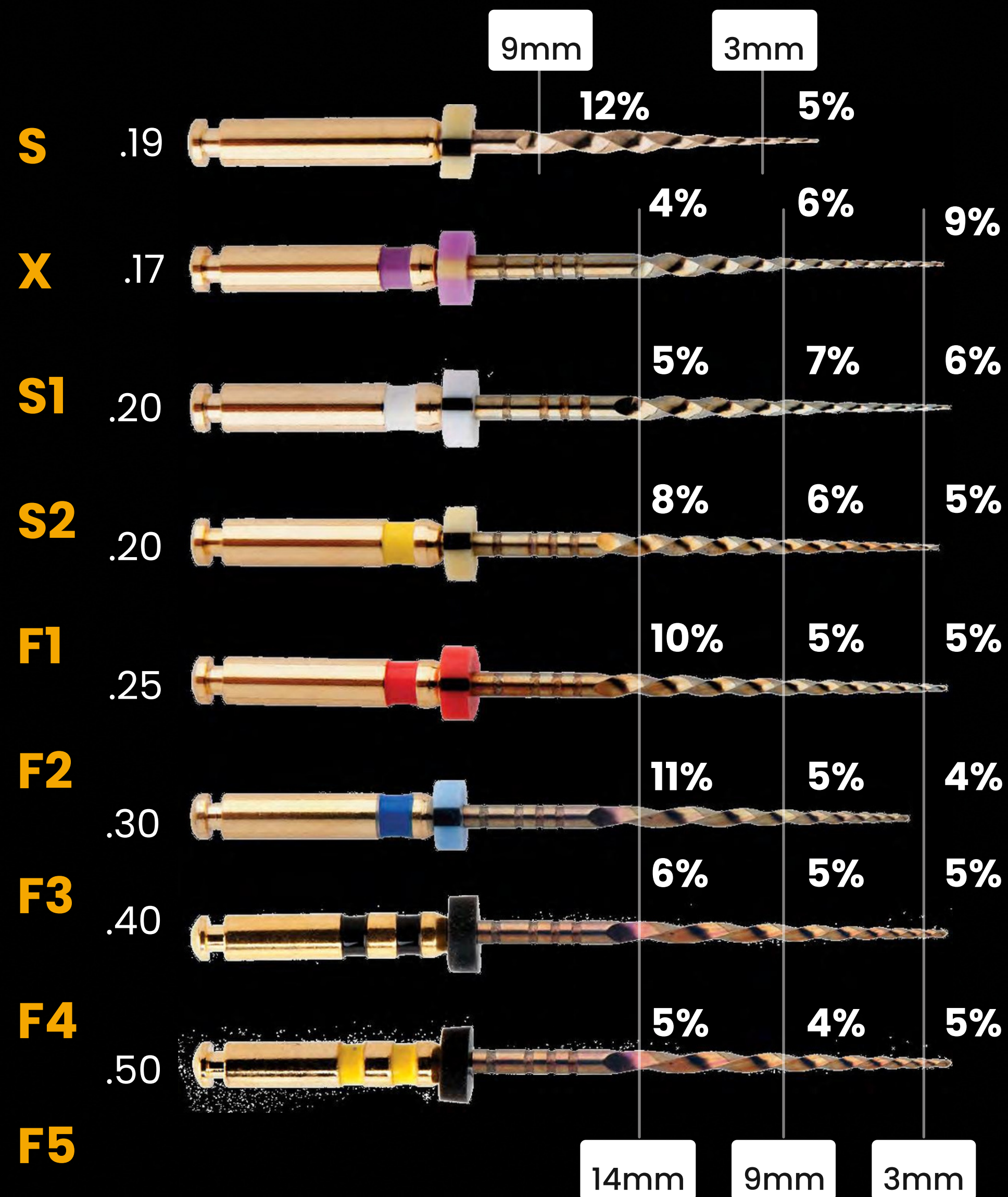
Endodontics, Hybrid heat treatment, Ni-Ti rotary instruments, Root canal treatment.

EDGETAPER
PLATINUM™

Try out the products!



EDGETAPER PLATINUM™



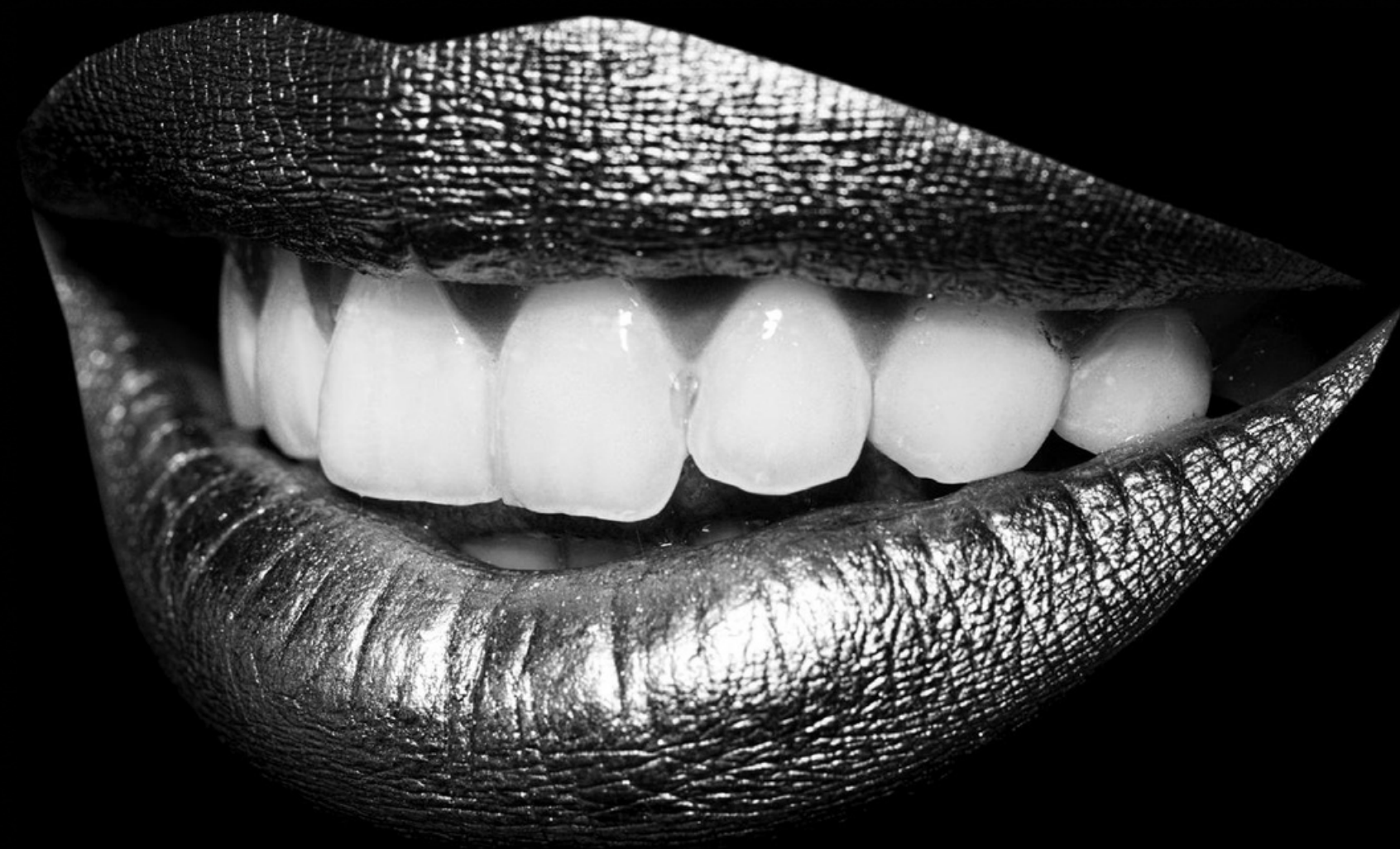The EdgeTaper Platinum™ is designed to be compatible with most handpieces and operates at the ProTaper® and ProTaper Gold® parameters. This familiar sequence will ensure the switch to EdgeTaper Platinum™ will be seamless.

EdgeTaper Platinum™ features our Heat-Treated Firewire™ NiTi making it strong and more flexible with 90° curves. EdgeTaper Platinum™ tests at twice the cyclic fatigue as ProTaper Gold® and 6 times the cyclic fatigue as ProTaper®.

Both file systems have a bloated triangular cross section with a progressive changing taper. Available in lengths 21mm, 25mm, 31mm with six of the same size file in each pack. Experience the new standard in file safety and canal centering ability.

EDGETAPER
PLATINUM™

The Taper
Has Been
Edgeified



Unmatched Flexibility – Heat-treated FireWire™ NiTi gives amazing flexibility, capable of 90° curves.

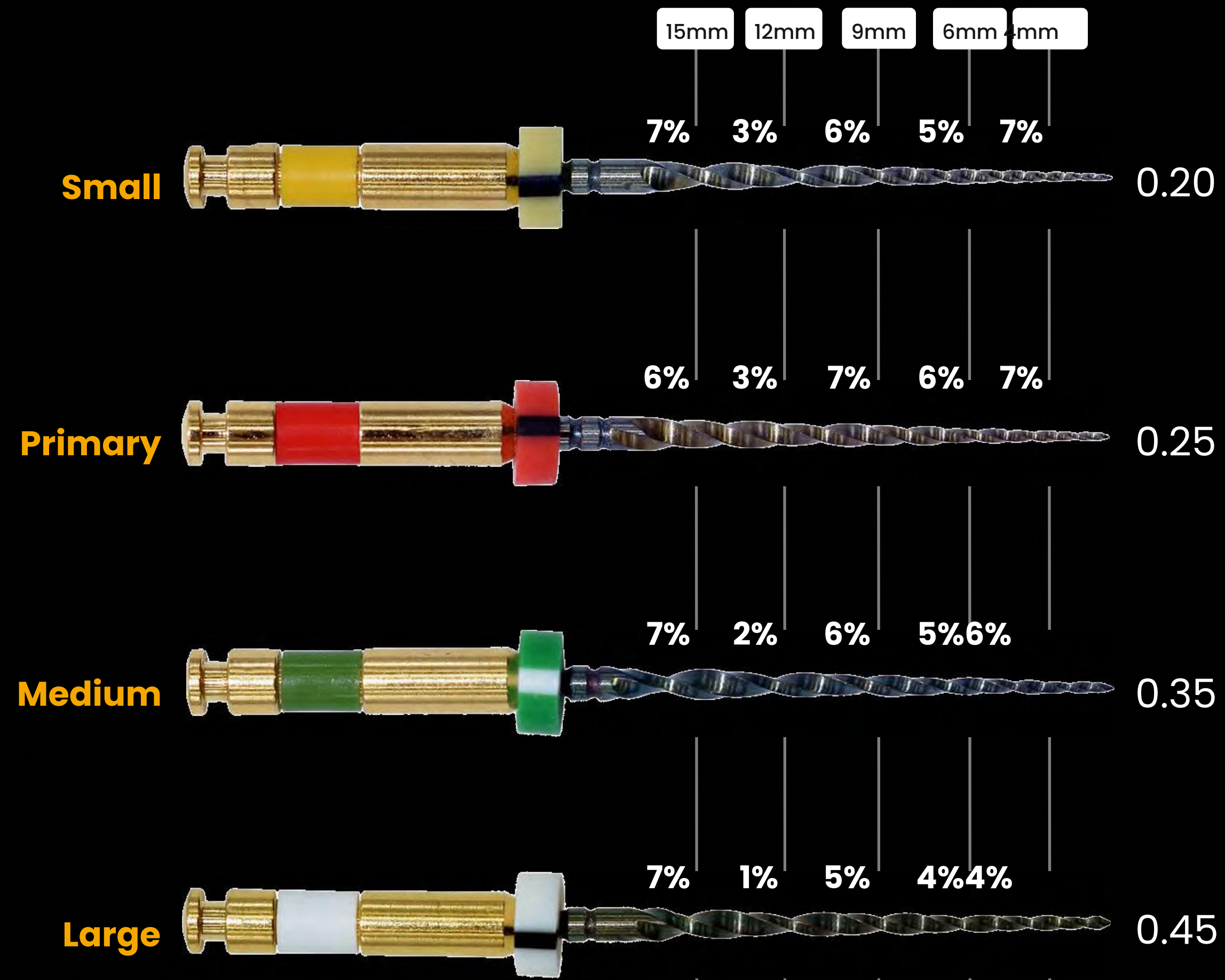


No Bounce Back – FireWire™ NiTi doesn't bounce back to preserve apical anatomy



Incredible Strength – Twice the cyclic fatigue as Protaper Gold® and six times that of ProTaper®

EDGEONE FIRE™



EdgeOne Fire™ features our Heat-Treated Fire-Wire™ NiTi and is designed to shape canals in a reverse-reciprocating motion. EdgeOne Fire works with existing handpieces operated at the Wave One® Gold parameter. EdgeOne Fire tests at five times the cyclic fatigue as WaveOne® Gold.

EdgeOne Fire™ is available in sizes Small, Primary, Medium and Large. Files have a parallelogram shaped cross section with a variable taper.

There are three files in each pack with the option of an assortment pack or single sized pack. Available in lengths 21, 25 and 31mm.

EDGEONE FIRE™

EdgeOne Fire™ is designed with a varied taper and shapes canals in reverse – reciprocating motion.



Unmatched Flexibility

Heat-treated FireWire™ NiTi gives amazing flexibility, capable of 90° curves.



No Bounce Back

FireWire™ NiTi doesn't bounce back to preserve apical anatomy



Incredible Strength

5x the cyclic fatigue as WaveOne® Gold.



We believe premium technology shouldn't have to come with a premium price tag.

Performance

Price

Technology

Contact us:

TO BE FILL OUT WITH TRANSLATION

